

Constrained Rotating Hinge Prostheses in Severe Haemophilic Knee Osteoarthritis

VLAD VERINGA¹, WILHELM FRIEDL², NORIN FORNA^{1*}, ANDREI IVAN^{3*}, NINA FILIP^{4*}, BOGDAN PUHA¹

¹Grigore T. Popa University of Medicine and Pharmacy, Iasi, Romania, Faculty Of Medicine, Department of Orthopedics and Traumatology, Surgical Sciences (II), 16 Universitatii Str., 700115, Iasi, Romania

²Wertheim Hospital, Department of Orthopedics and Traumatology, Germany

³Grigore T. Popa University of Medicine and Pharmacy, Iasi, Romania, Faculty Of Medicine, Department of Paediatric Orthopedics, Surgical Sciences (II), 16 Universitatii Str., 700115, Iasi, Romania

⁴Grigore T. Popa University of Medicine and Pharmacy, Iasi, Romania, Faculty Of Medicine, Department of Morpho-functional Sciences (II), 16 Universitatii Str., 700115, Iasi, Romania

The purpose of this experimental study is to present the design and biomechanical characteristics of cemented total knee prostheses type rotating-hinge RT-PLUS[®] (Smith&Nephew), as well as to evaluate their use in severe haemophilic knee arthropathy with major bone damage, ligamentous lesions, axial deviations and muscle retractions. We retrospectively evaluated 5 patients with severe haemophilic arthropathy with an average age of 48.5 years. The functional results are good, with a significant improvement of range of motion (ROM) and pain relief resulting in a much better life quality. We did not have any stem loosening or any other complications except 2 wound healing problems which were treated successfully. The authors recommend this type of arthroplasty in severe haemophilic knee arthropathy or in any primary knee osteoarthritis with severe bone loss or any kind of ligamentous lesions.

Keywords: haemophilic arthropathy, rotating-hinge prostheses, knee arthroplasty, major bone damage, range of motion

Haemophilia represents a hereditary coagulopathy caused by the deficiency of coagulation factor (fVIII in type A, fIX in type B), clinically characterized by repeated bleeding episodes which lead to the main complication - haemophilic arthropathy [1].

The topography of the affected joints is in decreasing order: knee - 36%, ankle -30%, elbow -23%, wrist -6%, shoulder -3%, hip -2% [2-4].

While the cartilage reconstruction is not a treatment option in haemophilic arthropathies, [5] this complication is approached differently, according to the degree of articular damage. Surgeons are starting with minimally invasive procedures, such as intraarticular infiltrations with viscoelastic substances [6], arthroscopic synovectomy, radiosynovectomy and end with complex procedures represented by total knee arthroplasties in advanced stages [7-10].

Advanced haemophilic knee arthropathy differs to primary knee osteoarthritis due to advanced process of fibrosis around periarticular soft tissue, muscle contractures in flexion, poor bone quality, severe bone destruction and major axial deviations [1,7-9,11].

The rotating hinge prostheses was initially designed to restore the articulation after large resections, within oncological limits, in patients with malignancies around the knee. The initial mechanism of these prostheses was a fixed hinge with no rotational motion, which had poor results, with multiple local complications, among which there were periprosthetic osteolysis, early loosening and marked pain caused by the major restrictions of articular biomechanics. Subsequently, brand new and reviewed generations of rotating hinge prostheses were designed, with better outcomes [12-14].

The aim of this study is to present the design and biomechanical characteristics of the cemented, postero-stabilised total knee prostheses, type rotating-hinge RT-PLUS[®] (Smith&Nephew), but also to analyze the results of

5 haemophilic patients with severe arthropathies, who underwent surgery in our department.

Experimental part

The experimental study was carried out on a number of 5 haemophilic patients who benefited from total knee arthroplasty with metaphyseal-cemented prosthesis type RT-PLUS[®] (Smith&Nephew), in the Comprehensive Haemophilic Center from University Emergency Hospital Sf. Spiridon Iasi, Romania, between January 2017-January 2018

Prosthetic design

Knee prosthesis type RT-PLUS[®] is a rotating-hinge cemented prosthesis [15]. This is made up of 3 components (femoral component, tibial component, polyethylene insert PE), which facilitate an internal/external rotation of approximately 10°. This prosthesis is available in 5 sizes (2,4,6,8,10); each of which can be combined with the next size up or down. Femoral and tibial components are fixed in the bone through the intramedullary cemented stems. These are thin and relatively short which enables them to be introduced into narrow diaphysis.

The femoral component is asymmetrical and made up from a cobalt-chrome-molybdenum alloy (fig. 1A). This presents a 40mm rotating hinge which confers excellent protection against dislocation and ensures a smooth coupling characteristics of the components [fig. 1B] and a deep patellar ditch, which offers an increased stability to the expanding mechanism (fig. 1C). The specific design of the femoral component allows as little as possible bone resection, which leads to decreased chances of condyle fractures.

The tibial insert is made up of UHMW-polyethylene and it comes in different sizes (8,11,14mm) in order to re-establish easily the height according to osteotomy of the tibial plateau (fig. 1D).

* email: norin.forna@gmail.com; ivan.andrei89@gmail.com; zamosteanu_nina@yahoo.com

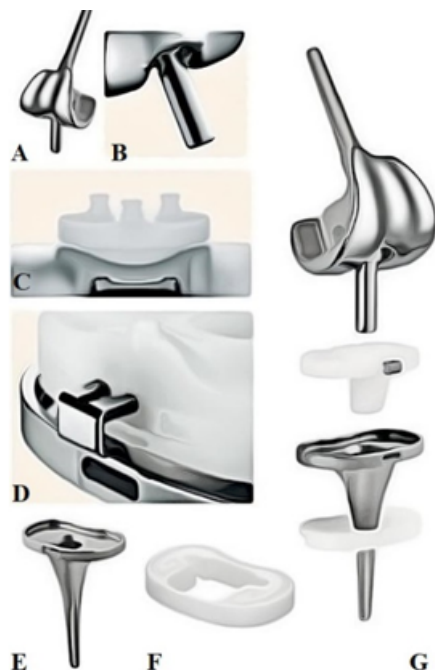


Fig. 1. A-G - Design of the total knee prosthesis type rotating hinge RT-PLUS® (Smith&Newphew).

- A - Femoral component. B - Femoral component showing the rotating hinge mechanism. C - Patella standing on the patellar groove. D - PE insert locking system on the tibial plateau. E - Tibial component. F - Tibial PE block for bone defects compensation. G - Coupling components of the prosthesis.

Adapted image from [15]

The tibial component is made from a cobalt-chrome-molybdenum alloy and prevents PE insert wear by the special coupling mechanism, without allowing friction between the 2 components (fig. 1E).

The tibial block is made of 10mm high PE and is available to compensate for tibial bone defects (fig. 1F).

The retrospective study was carried out on 5 patients with a mean age of 48.5% (limits 35-62 years old) with type A haemophilia; 3 of them with severe form (FVIII<1%) and 2 of them with moderate form (FVIII=1-5%) (table 1). Four patients presented no inhibitors and one of them presented inhibitors. All patients have post-transfusional virus C hepatitis.

The patients without inhibitors underwent pre-, intra- and postoperative haemophilic treatment with substitution factor MOROCTOCOG Alpha in compliance with National Haemophilia Protocol [16]. The one with positive inhibitors (2,3 Bethesda units) underwent treatment with substitution factor Recombinant Alpha Eptacog and Tranexamic Acid in compliance with Giangrande Protocol [17,18].

Surgical technique

After a thorough preoperative planning, we placed the patients in supine position, under general anesthesia and we used a tourniquet at the baseline of the thigh. The leg was fully isolated, in order to be easily maneuvered during the surgery. In all the 5 cases, we used the internal parapatellar approach with medial arthrotomy (fig. 2A). After the usual articular debridement (synovectomy, meniscectomy, Hoffa fat excision, marginal osteophyte excision), we excised the collateral and cruciate ligaments, in order to facilitate the articular mobility, while

Table 1
HAEMOPHILIC TYPE, TREATMENT AND ASSOCIATED COMORBIDITIES OF THE PATIENTS

Patients	Age	Haemophilic type	Inhibitors	Comorbidities	Substitution treatment	Ac. tranexamic
N.M.	40 y.o.	Haemophilia type A, moderate form FVIII=1-5%	No inhibitors	1. Virus C hepatitis 2. Severe left knee osteoarthritis 3. Left genu-varum 4. Osteoporosis	Moroctocog alfa (National Haemophilic Protocol)	NO
C.I.	47 y.o.	Haemophilia type A, moderate form FVIII=1-5% + FVII deficit	No inhibitors	1. Virus C hepatitis 2. FVII deficiency 3. Bilateral knee osteoarthritis	Moroctocog alfa (National Haemophilic Protocol)	NO
I.F.	52 y.o.	Haemophilia type A, severe form FVIII<1%	No inhibitors	1. Virus C hepatitis 2. Bilateral severe knee osteoarthritis 3. Bilateral genu flexum	Moroctocog alfa (National Haemophilic Protocol)	NO
P.C.	50 y.o.	Haemophilia type A, severe form FVIII<1%	No inhibitors	1. Virus C hepatitis 2. Bilateral severe knee osteoarthritis with left genu varum and genu flexum 3. Left hip osteoarthritis 4. Left knee hemarthrosis	Moroctocog alfa (National Haemophilic Protocol)	NO
M.C.	48 y.o.	Haemophilia type A, severe form FVIII<1%	With inhibitors (2,3 Bethesda units)	1. Virus C hepatitis 2. Bilateral knee osteoarthritis 3. Right knee ankylosis	Recombinant Alpha Eptacog (conform protocol Giangrande)	YES

all patients have an important soft tissue retraction. We continued with opening the femoral canal in order to place the osteotomy block for the transversal distal femoral bone cut, then the one for transversal tibial proximal osteotomy. We checked the flexion gap in 90° flexion and in full extension and checked the stability in frontal plane. Further, we did the specific oblique, anterior and posterior femoral osteotomies (fig. 2C-F). The patella was denervated but not resurfacted. Following this stage, the trial components were fixed according to the chosen sizes and we checked their positioning and stability in all planes (fig. 2G). The last stage consists of assembling the final prosthetic components, only metaphyseal cemented. (fig. 2H-J).

Postoperative X-rays reveal good calibration and positioning of the prosthetic components (fig 2B).

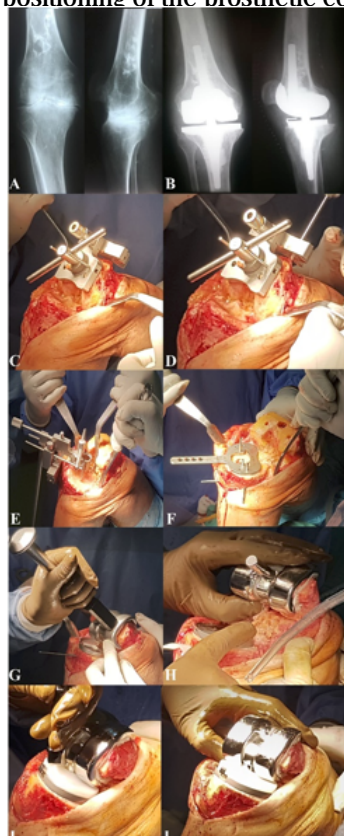


Fig. 2 A-H - Intraoperative images of a total knee arthroplasty with a rotating hinge prosthesis RT-PLUS®.

A-B - Preoperative and postoperative X-rays.
C-D - Femoral osteotomy block. E - Tibial extramedullary guide.
F - Tibial plateau sizer.
G - Inserting femoral temporary component.
H - Definitive femoral component. I - Inserting PE meniscus in the tibial component. J - RT-PLUS® prosthesis

The interventions lasted approximately 90 min. In two cases it was installed a suction drainage which kept functioning for about 48h after the surgery.

In the following days, there were no bleeding events and the normalised coagulation profile due to substitution treatment prompted the use of Enoxaparin 0.4mL per day in all 5 cases.

Immediately after surgery, under substitution treatment, all 5 patients began walking with total weight bearing with ambulation frame, functional rehabilitation treatment with passive motion - arthromotor (-10° extension and 70-80° flexion) and assisted active progressive articular motion.

All patients were regularly monitored after the surgery, both clinically and imagistic, at 3 weeks, 6 weeks, 3 months and every 3 months after, including rehabilitation program.

Results and discussions

The patients presented favorable hematological evolution, except one patient with minimal bleeding as a secondary effect of FVII deficiency and required a single unit blood transfusion.

Two of them presented local hematoma which led to rehabilitation temporization and imposed rest, elastic bandages and cryotherapy. One of them remitted spontaneously and the other one was evacuated.

Due to wound healing problems, skin retraction and low soft tissue, one patient had skin necrosis which needed surgical excision and negative pressure therapy [19].

The recovery of joint mobility remained constant and patients currently have an active flexion 70-80° with extension of -15°. Two patients with limitation of movement required long-term rehabilitation with no arthroscopic treatment for arthrofibrosis [20].

During functional rehabilitation, there were no complications from the hematological point of view since the patients were under substitutive treatment with Moroctocog Alpha for those who had no inhibitors and with Recombinant Alpha Eptacog for the one with inhibitors.

From the orthopaedic point of view, the evolution of these patients was favorable in all 5 cases, with pain reduced considerably, excellent improvement of joint mobility and life quality (table 2).

Table 2
CLINICAL RESULTS

Patient	Active range of motion	Bleeding	Wound problems	Days hospitalised in orthopaedic department
N.M.	Flexion= 100° Extension= 0°	No	No	13 days
C.I.	Flexion= 75° Extension= -15°	Yes (FVII deficiency associated). Knee hematoma which was punctured.	Yes.	18 days
I.F.	Flexion= 90° Extension= -10°	No	No	18 days
P.C.	Flexion = 50° Extension= -5°	No	Yes, with limited necrotic tissue excision and negative pressure therapy	14 days
M.C.	Flexion= 60° Extension= -5°	Yes	Yes	11 days

Rotating-hinge prosthesis type have also been studied by other authors before. Barrack carried out a study on 23 patients suffering from severe knee osteoarthritis, where total knee rotating-hinge prosthesis type was used, tracking in a period between 2 and 9 years, the range of motion and life quality of the patient. He did not notice any difference between this type of prosthesis and standard prosthesis [12].

Pour A et al carried out a study on a larger group of patients, by tracking 44 patients in a period of approximately 4.2 years, where total knee arthroplasty with rotating-hinge prostheses was used. He noticed a substantial improvement of quality life and pain release, but with a relatively big number of complications (3 patients with deep local infection, 4 patients with loosening) [21].

Kowalczewski et al reported, in a 10-year study carried out on patients who underwent total primary knee arthroplasty, that he did not revised any of the prosthesis component and no mechanical complication was recorded. He chose rotating-hinge prostheses in severe arthroses with major bone damage, severe ligamentous injuries and marked joint rigidity, similar to the patients studied by us. They also didn't resurfactate the patella and the patello-femoral complications were minimum. They have noticed a major improvement in the joint mobility on operated patients, on patient life quality and pain release. [22]

Despite the major functional impairment in haemophilic severe osteoarthritis, osteoporosis. [23] and deformities, the demanding surgery with rotating-hinge prostheses assured on outcome improvement with pain relief and excellent well-being for all patients.

Conclusions

Total metaphyseal cemented knee prosthesis type rotating hinge RT-PLUS® (Smith&Nephew) is an innovative prosthesis that confers multiple advantages in severe haemophilic knee osteoarthritis which are characterized by severe bone damage and soft tissue lesions.

The excellent functional results, the quality of life and ROM improvements convinced the authors to recommend this type of prosthesis for use in primary surgery at patients with severe knee osteoarthritis, ligamentous injuries and axial deformities.

Even if the initial cost of these demanding elective surgeries is high, it may be recovered in the following years by abolition of any other bleeding episodes within the affected joint.

References

1. SRIVASTAVA A, BREWER AK, MAUSER-BUNSCHOTEN EP et al. Guidelines for the management of hemophilia. *Haemophilia* 2012;1-47.
2. WHITE G, ROSENDAAL F, ALEDORT LM, LUSHER JM, ROTHSCILD C, INGERSLEV J. Definitions in hemophilia. Recommendation of the scientific subcommittee on factor VIII and factor IX of the scientific and standardization committee of the International Society on Thrombosis and Haemostasis. *Thromb Haemost* 2001; 85: 560.
3. BERNTORP E, COLLINS P, D'OIRON R et al. Identifying nonresponsive bleeding episodes in patients with haemophilia and inhibitors: a consensus definition. *Haemophilia* 2011; 17: e202-210.
4. SIRBU P.D., TUDOR R., BEREA G., SCRIPCARU A., CIUBARA B., BADULESCU O.V. Bipolar Polyethylene Radial Head Arthroplasty in

Posttraumatic Unstable Elbows. Prosthetic design and clinical results, *Revista de Materiale Plastice*, 2017, 54 (2): 298-301; ISSN 0025-5289

5. BENE A H, TOMOAI G, SORITAU O, PASCA RD. A review on the reconstruction of articular cartilage using collagen scaffolds. *Rom Biotech Letters*. 2016; 21(4):11735-11742.
6. SIRBU P.D., TUDOR R., BADULESCU OV. Hyaluronic Acid and Chondroitin Sulfate Viscosupplementation in Severe Arthropathy of Hemophilic Patients, *Rev.Chim. (Bucharest)*, **68**, no.5, 2017, p.1028-1030
7. RODRIGUEZ-MERCHAN E.C., LEONARD A VALENTINO. Orthopedic disorders of the Knee in hemophilia: A current concept review. *World J Orthop* 2016;7(6):370-375.
8. RAFFINI LESLIE, MANNO CATHERINE. Modern management of haemophilic arthropathy. *British Journal of Haematology* 2007;136:777-787.
9. RODRIGUEZ-MERCHANT EC. Aspects of current management; orthopaedic surgery in haemophilia. *Haemophilia* 2012;18:8-16.
10. HILGARTNER MW. Current treatment of hemophilic arthropathy. *Curr Opin Pediatr* 2002;14:46-49.
11. RODRIGUEZ-MERCHAN E.C. Orthopedics surgery is possible in hemophilic patients with inhibitors. *Am J Orthop* 2012; 41(12):570-574.
12. BARRACK R.L. Evolution of the rotating hinge for complex total knee arthroplasty. *Clinical Orthopaedics and Related Research*, no. 392, pp. 292-299, 2001.
13. BARRACK R.L. Rise of the rotating hinge in revision total knee arthroplasty. *Orthopedics*, vol. 25, no. 10, pp. 1020-1058, 2002.
14. GUDNASON A., MILBRINK J., HAILER N.P. Implant survival and outcome after rotating-hinge total knee revision arthroplasty: a minimum 6-year follow-up. *Archives of Orthopaedic and Trauma Surgery*, vol. 131, no. 11, pp. 1601-1607, 2011.
15. ***<http://www.smith-nephew.com/education/resources/literature/surgical-guides/orthopaedic-reconstruction-/surgical-technique1/>
16. BADULESCU O.V., TUDOR R, FRIEDL W, SCRIPCARU A, SIRBU P.D. Moroctocog Alfa Efficacy in Hemostasis Management in A Type Hemophilia Patients with Elective Arthroplasty. *Rev.Chim. (Bucharest)*, **69**, no. 6, 2018.
17. GIANGRANDE P. L. F. et al., Consensus protocol for the use of recombinant activated factor VII [eptacog alfa (activated); NovoSeven] in elective orthopaedic surgery in haemophilic patients with inhibitors, *Haemophilia* (2009), 15, 501-508.
18. BADULESCU O.V., TUDOR R, BLAJ M, CIUNTU B.M., SIRBU P.D. The Efficiency of Recombinant Alpha Eptacog in Haemostatic Management of Haemophilic Patients with Elective Arthroplasty. *Rev.Chim. (Bucharest)*, **68**, no. 8, 2017.
19. CIUNTU B.M., VASILUTA C., NEGRU R., HULTOANA R., CIUNTU R., GEORGESCU SI O., SIRBU P.D., AZOICAI D. Negative Pressure Therapy in the Surgical Treatment of Diabetic Foot, *Rev.Chim. (Bucharest)*, **68**, no.7, 2017, p.1648-1651
20. OLTEAN-DAN D., GABRI J.Z., APOSTU D., PAISAN M.G., DAN P.C., BARDAS C.A., TOMOAI G., BENE A H. Arthroscopic Treatment of Patients with Arthrofibrosis Following Total Knee Replacement. *Rev.Chim. (Bucharest)*, **69**, no.11, 2018, p.:3292-3295.
21. POUR A, PARVIZI J, SLENKER N. et al. Rotating hinged total knee replacement: use with caution. *J Bone Joint Surg Am* 2007;89:1735.
22. KOWALCZEWSKI., MARCZAK D., SYNDER M., SIBINSKI M. Primary Rotating-Hinge Total Knee Arthroplasty: Good Outcomes at Mid-Term Follow-Up. *The Journal of Arthroplasty* 29 (2014) 1202-1206.
23. SIRBU P.D., TUDOR R., VERINGA V., CIUNTU B.M., RADU V., CIUBARA B., BADULESCU O.V. Strontium Ranelate in the Healing of Fractures Complicated with Delayed Union. It is Really Effective? *Rev.Chim. (Bucharest)*, **68**, no. 8, 2017, p.1825

Manuscript received: 05.10.2018